

## Principles of Metacarpal Fracture (Management & Treatment)

Dr. Zaher Osman

Department of Orthopedic, Ali Abad Teaching Hospital, Kabul Medical University, AFGHANISTAN.

Corresponding Author: zaher.osman210@gmail.com



www.jrasb.com || Vol. 1 No. 4 (2022): October Issue

Received: 22-09-2022

Revised: 13-10-2022

Accepted: 23-10-2022

### ABSTRACT

The hand is essential in humans for physical manipulation of their surrounding environment. Allowing the ability to grasp, and differentiated from other animals by an opposing thumb, the main functions include both fine and gross motor skills as well as being a key tool for sensing and understanding the immediate surroundings of their owner.

Hand fractures are the most common fractures presenting at both accident and emergency and within orthopedic clinics. Appropriate evaluation at first presentation, as well as during their management, can significantly prevent both morbidity and disability to a patient. These decisions are dependent on a wide range of factors including age, hand dominance, occupation, and co-morbidities.

A fracture is best described as a soft tissue injury with an associated bony injury. Despite this being the case, this paper intends to deal mainly with the bone injury and aims to discuss both the timing, as well as the methods available, of hand fracture management.

Fractures of the metacarpal are the most common of hand fractures accounting for up to 40% [1, 2] and are usually the injury described as 'a broken hand' by the general public. For discussion purposes fractures of the metacarpals are best described anatomically and the digits can be grouped together, although the fifth metacarpal is often expressed on its own as the 'boxer fracture' and accounts for a quarter of all metacarpal fractures [2]. Likewise, due to anatomical and functional variance the first metacarpal is generally classified as a separate entity which is not included in this Article.

**Keywords-** Fracture, metacarpal, injury, hand, External Fixation, k wire, plates.

## I. INTRODUCTION

### A. Metacarpal Anatomy- A Brief Review

The main body of the hand is formed by the five metacarpal bones and is commonly referred to as the palm. The metacarpal bones are numbered one to five, with one corresponding to the thumb and five the little finger. Each metacarpal has a base that articulates with the distal row of carpal bones. The body or shaft of each metacarpal is curved and this gives the palm of the hand its characteristic cup shape. The shaft of each metacarpal widens at its distal end to form a neck and finally the metacarpal head. The dorsal surface of each metacarpal head is broad and flat, whilst the palmar surface has a central depression for the passage of the flexor tendons. The heads of the metacarpals are prominent structures and can easily be felt especially when the hand is made into a fist. They articulate with the proximal phalanx of each

digit to form the metacarpal-phalangeal joints (MCPJ), which are more commonly known as the 'knuckles. These are condyloid joints that allow flexion and extension of the digits, as well as a very small degree of abduction and adduction when the digits are extended.

### B. Metacarpal Fractures

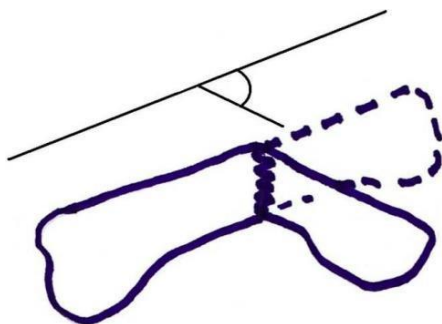
Fractures of the metacarpal bone either involve the proximal base, the shaft, neck, or the distal head. The neck and shaft are more commonly injured in contradiction to the first metacarpal where the base is most often involved.

Fractures of the metacarpal head are by definition intra articular and are rarer than fractures involving the distal parts of the bone. The second metacarpal is the most common to be injured, and the cause is often as a result of a direct blow or crush injury. Fractures in this region are often comminuted, causing additional difficulty with their management. These

injuries generally require open reduction and fixation although it is reported that metacarpal head fractures can be treated conservatively, with good long-term outcome if there is less than 25% joint involvement [7].

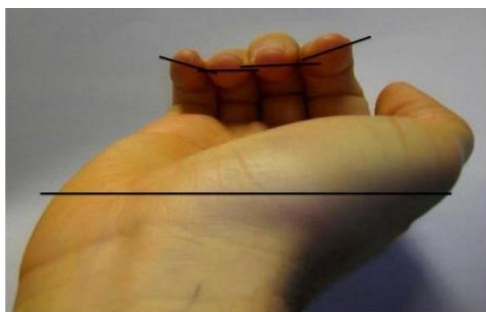
The neck of metacarpal is the most common site of fracture and is greatest in the two ulnar border digits, 4 and 5. The shaft of the metacarpal is also referred to as the body. The shaft can be fractured in 3 ways, oblique, transverse or spiral, and comminuted with the least protected fifth metacarpal at highest risk of injury [8]. Rotational deformity is greater in injuries to the shaft.

Both neck and shaft fractures are characteristically related to axial loading or direct trauma. Both typically angulate with a dorsal apex (Fig. 3). This angulation is often accepted due to the carpometacarpal (CMC) joint range of movement that can compensate for angles up to 10-15 degrees in the index and middle finger, and 20 degrees in the ring. The more proximal the fracture generally the greater the angulation, and the more noticeable any hand deformity such as clawing becomes. It has been reported that volar angles up to 70 degrees have been tolerated with conservative management and no long-term functional deficit [9].



**Fig. (3). Angulation measurement of metacarpal fracture.**

The Boxer's fracture is a fracture involving the fifth metacarpal neck. There is no stabilisation along its ulnar aspect (the other digits have a neighbouring bone) and therefore fractures result in the metacarpal head being freed from any proximal attachments. This allows the



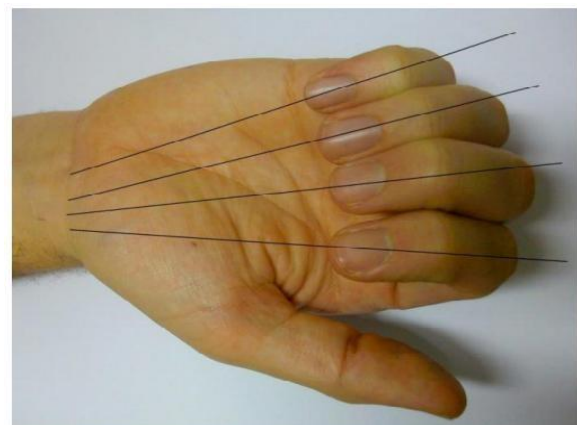
**Fig. (2). Examination of rotation of the fractured digit.**

The fingers should be held with the MCPJ, PIPJ and DIPJ flexed and the angle of the nail should correspond to the plane of the palm. Some rotation may

be normal for the patient (as in index and little finger in example).

head to rest in a greater volar angle and if left long term causes reduced metacarpal flexion due to collateral ligament shortening. Angulation of the head below 30-40 degrees is often acceptable in the fifth metacarpal, again thanks to CMC joint movements [10] and again angles up to 70 degrees have been successfully managed conservatively [11].

Fractures at the metacarpal base are the most stable of the metacarpal fractures due to both dorsal and palmar carpometacarpal, and the interosseous, ligaments. This stability is greatest in the second and third digits as there is some greater mobility allowed in the ulnar sided fourth and fifth digits [12]. They are generally classed as intra or extra-articular. Insertion of the flexor and extensor carpi muscles into the metacarpal bases (Radialis into the second and third metacarpal, and ulnaris into the fourth and fifth) can potentially aggravate any deformities. Intra-articular base of metacarpal fractures are uncommon but there may have a tendency of being both under-reported and diagnosed thanks to the stability of the surrounding structures [13].



**Fig. (1). The direction of the fingers when flexing to make a fist: pointing towards the area of the scaphoid tubercle. These lines are disrupted when the finger is rotated with the rotated finger lying under neighboring digits.**



## II. METHOD & MATERIAL

Management of fractures to the metacarpal bones of the hand is decided on both the clinical examination and radiological findings. The reasons behind this are that the hands long-term function is often dependent on the fractures angulation and rotation.

The key parts of the clinical examination is to assess the degree of rotational deformity, and whether there is any soft tissue compromise, including evidence of compound fractures with or without the involvement of a 'fight bite.' This term relates to the high incident of hand fractures secondary to punches and that a number of these involve a punch to an individual's mouth and thus an accidental 'bite' to the skin. Inability to extend at the metacarpophalangeal joint also correlates to increased need of operative fixation.

Rotation of the digit impacts greatly on functional grip, and can be a source of chronic pain [3]. It is best assessed by asking the patient to make a fist. The digits of all 4 fingers should point towards the scaphoid tubercle, without overlapping with the MCPJ and PIPJ flexed (Fig. 1). Likewise the nail should appear parallel to the hand and neighbouring digits when looking endon (Fig. 2). The digits should then tuck in as the DIPJ is flexed, although pain often restricts a degree of the flexion of all these joints. Comparison should be made to the other hand, but there is now a feeling that both digit overlap and nail alignment vary greatly within the population, making the clinical examination all the more difficult [4-6].

The radiological findings correlate to the angulation of the fracture, as well as metacarpal shortening. Metacarpal shortening appears to consequently affect interosseous function with a 10mm loss of length corresponding to up to 55% muscle power loss [7].

Radiological views of the individual metacarpals are not possible. Posteroanterior and oblique views are mandatory.

Ulnar digit injury lateral views should be optimally taken with 30-degrees pronation, and the radial digits with 30 degrees supination. However, angulation of the metacarpal bones is often best seen with a true lateral view. The Brewerton view can be useful if collateral ligament avulsion injury is suggested, and is taken with the MCPJ flexed at 65 degrees and the radiological view angled at a 15-degree angle ulnar to radial.

## III. DISCUSSION

### (1) *Non-Surgical Management of Metacarpal Fractures*

Literature regarding management of any of the above fractures involving the metacarpals is vast although there appears to be no full consensus on particular pathways [14].

Non-operative techniques involve buddy strapping the injured digit to a neighbouring digit, with or without the application of varying degrees of splint including thermoplastic moulds or Plaster of Paris (POP) back slabs or cast. It is generally regarded that the 'buddy' or 'neighbour strap' reduces the risk of rotational deformity. Conventional teaching suggests splintage of the fracture with an aim of 20 degrees wrist extension, the metacarpophalangeal joint in 60-70 degree flexion and interphalangeal joint extension [15].

This approach is described to reduce consequent ligament shortening and consequent reduction in initial and long-term hand function. However, several studies have suggested that both the degree of metacarpophalangeal extension or flexion as well as the amount of interphalangeal joint immobilisation does not have a significant impact on long term function, when looking at extra-articular fractures [16, 17]

One study reported good results with simple buddy strapping of the fractured fifth shaft to the ring finger as compared to a gutter POP, with no difference of function at twelve weeks as well as the former group having little to no hospital interaction after initial strapping and advice [18]. McMahon et al., found no significant difference between a compression bandage splint and POP managed stable shaft fractures, with a view for three-week immobilization [14].

Metacarpal base fractures that are un displaced and impacted can be conservatively managed [10].

Non-surgical management of the majority of shaft and neck fractures is generally accepted, as long as suitable reduction has occurred [7, 16].

This is particularly noticeable in isolated third and fourth metacarpal fractures where the bones are well supported by the adjacent bones and strong intermetacarpal ligaments. Reduction of the angulated fracture can be attempted in the emergency setting, and is best done with the hand in 90 degree flexion at the metacarpophalangeal and proximal interphalangeal joints. Pressure is then applied on the dorsal aspect of the fracture with an attempt to 'push' the metacarpal head dorsally and flattening the shaft [12]. This technique can be attempted for closed fractures and although allows good reduction of the fracture, it is difficult to maintain this position as the hand cannot be splinted in this position due to long term clawing and flexion contracture formation, and the hand is placed in the above conventional position for POP application.

Again reports seem to support both conservative and operative management for metacarpal base fractures. Those with no or minimal displacement have been found to have satisfactory results in hand function, especially grip, with wrist immobilisation for 4 weeks [13].

Those with displacement can be treated with reduction of the fracture and K wire fixation, with subsequent POP for a similar time period [3-5]. One paper [6] where only base of fifth metacarpal fractures were treated, and all conservatively, appears to describe

complications such as metacarpal shortening and joint problems which are not commented on in the other papers, and may suggest these complications do not occur with operative fixation.

## (2) *Surgical Management of Metacarpal Fractures*

Indications for surgery include; open fractures, intraarticular fractures, angulation of the fracture greater than 30 degrees, rotational deformity greater than 10 degrees and gross (>5mm) shortening of the metacarpal [7]. Likewise the irreducible or unstable fracture requires operative management, as does multiple digit involvement.

If the fracture is open, or a compound fracture, this requires formal debridement and irrigation, as well as appropriate antibiotic cover, and this can be done with reduction with or without fixation. Human bites, including the fight bite scenario, require intravenous antibiotics. Injuries involving extensive soft tissue loss, with or without bony injury require operative management too. Cosmetic and aesthetics of the hand may also precipitate surgical input.

Metacarpal fractures in general can be treated with Kirschner wire (K wire), screws or intraosseous wiring as well as the use of hand plates [8]. Each choice is more dependent on surgeon preference and skill rather than any particular benefit with the varying approaches [9]. Intraoperative radiography is generally required. Immobilisation for greater than two week is suggested with K wire fixation [5] and this method of fixation is generally believed to be the least invasive technique with maximum long-term function [10].

The fifth metacarpal often requires fixation after the base is fractured due to the deformity exaggerated by the pull of extensor, and to a lesser extent flexor, carpi ulnaris. K wires have long been the optimum management for these injuries. Intermedullary fixation of the fifth metacarpal neck fracture has been reported to give similar results to K wire fixation [3] although locking plates do not show any benefit and due to their cost do not justify their use [9]. With regard to how to pin this bone, intramedullary K wires have been shown to be more effective than a transverse approach but is more technically demanding [3].

In respect to the other metacarpals, shaft fractures can be stabilised with all the above techniques. In the case of transverse fractures, longitudinal K wires are best placed in a distal to proximal direction, whilst the use of cross pins should facilitate crossing of the pins near the fracture site. Transverse pins can be sited proximal (1 pin) and distal (2 pins) the fracture into the adjacent digits metacarpal.

Intramedullary and tension band wire fixation also give good long-term results although the former can be technically demanding and the latter involves an open route.

Oblique fractures of the shaft are amenable to longitudinal or transverse pinning as well as plate and screw fixation.

Multiple lag screw fixation is a choice for long spiral fractures and again choice is more dependant on surgeon choice.

Cadaveric studies showed comparable results, in terms of biomechanical strength, between biocritical interfragmentary screws and the more traditional lag screw [14] and is also shown to be a good alternative in the live patient [15].

One study showed good early mobilization and long-term function with no complications using cerclage wire fixation for these injuries [16]. External fixation is also an alternative but is more commonly used for severely comminuted injuries with loss of bone. Bone graft is a supplementary option in all of these injuries but is generally saved for bone loss related trauma.

Surgical fixation of the metacarpal fractures with plates does give good radiological reduction of fractures but does involve complications including nerve and soft tissue injury as well as increased incidence of stiffness secondary to inflammatory reactions from the surgery [15]. Plate fixation of extra articular fractures of the metacarpals has been found to have complication rates in up to 33% of patients including infection, complex regional pain syndrome and plate loosening [9]. These complications are counteracted by good immediate strength of the fracture fixation and so a quicker return to movement therapy [18].

Intramedullary nails have been shown to offer similar results to plate and screw fixation. The former requires a shorter operative time but was found to have a higher degree of secondary surgery for removal of the nail [13]. If the fracture requires fixation, with the development of microsurgery, mini screw fixation shows comparable results with that using K wire fixation. Bicortical self-tapping minis crews for oblique fractures and uni- and bi-cortical screws for transverse fractures offer similar results [18].

Regarding the metacarpal head, if there is greater than 12 mm articular displacement or greater than 15% involvement, an open approach through a dorsal approach is required. Again K wires, cerclage wiring and screws are options with the key being whichever choice, including conservative, has to allow early and appropriate mobilisation.

In severely comminuted fractures the use of external fixation or conservative management is often favourable where K wires often fail. As a last resort, arthroplasty is an option.

A literature study by Bushnell et al., concluded that the second and third metacarpal base have been generally more successful with open reduction and internal fixation as opposed to conservative management. This is also seen in the rarer base of fourth metacarpal fracture too [14]. Multiple metacarpal fractures in the one hand with a closed injury are not common, and Souer and Mudugal [18]. Suggest plate fixation is a suitable option and is a safe, reliable and consistently reproducible method.



As surgical techniques develop new methods are also being developed. For instance, bioabsorbable mini-plates for metacarpal fractures have been seen as a potential option with comparable results suggesting good stability in cadaveric studies [17]. There is increased concern regarding the absorbable implants with first designs involving foreign body reactions, which although improving implants appear to have reduced, may now just only be delayed, and require further study [11].

## REFERENCES

- [1] Ashkenaze DM, Ruby LK. Metacarpal fractures and dislocations. *Orthop Clin North Am* 1992; 23: 19.
- [2] Radiopaedia.org [homepage on internet] Metacarpal fractures. Available at: <http://radiopaedia.org/articles/metacarpal-fractures> (reviewed 20/10/2011)
- [3] Ford DJ, Ali MS, Steel WM. Fractures of the fifth metacarpal neck: is reduction or immobilisation necessary? *J Hand Surg* 1989; 14B: 165-7.
- [4] Birndorf MS, Daley R, Greenwald DP. Metacarpal fracture angulation decreases flexor mechanical efficiency in human hands. *Plast Reconstr Surg* 1997; 99(4): 1079-83.
- [5] Poolman RW, Goslings JC, Lee JB, Muller MS, Steller EP, Struijs PA. Conservative treatment for closed fifth (small finger) metacarpal neck fractures. *Cochrane Database Syst Rev* 2005; 20: CD003 210.
- [6] McNemar TB, Howell JW, Chang E. Management of metacarpal fractures. *J Hand Ther* 2003; 16: 143-51.
- [7] Tavassoli J, Ruland RT, Hogan CJ, Cannon DL. Three cast techniques for the treatment of extra-articular metacarpal fractures. Comparison of short-term outcomes and final fracture alignments. *J Bone Jt Surg* 2005; 87A: 2196-201.
- [8] Jahss SA. Fractures of the metacarpals: a new method of reduction and immobilization. *J Bone Joint Surg* 1938; 20(1): 178-86.
- [9] Roth JJ, Auerbach DM. Fixation of hand fractures with bicortical screws. *J Hand Surg* 2005; 30(1): 151-3
- [10] Al-Qattan MM, Al-Lazzam A. Long oblique/spiral mid-shaft metacarpal fractures of the fingers: treatment with cerclage wire fixation and immediate post-operative finger mobilisation in a wrist splint. *J Hand Surg* 2007; 32: 637-40.
- [11] Freeland AE, Orbay JL. Extraarticular hand fractures in adults: a review of new developments. *Clin Orthop Relat Res* 2006; 445: 133-45.
- [12] Bennett EH. Fractures of the metacarpal bones. *Dublin J Med Sci* 1882; 73: 72-5. [13] Foster RJ, Hastings H 2nd. Treatment of Bennett, Rolando, and vertical intraarticular trapezoidal fractures. *Clin Orthop Relat Res* 1987; (214): 121-9.
- [14] Carlsen BT, Moran SL. Thumb trauma: bennett fractures, Rolando fractures, and ulnar collateral ligament injuries. *J Hand Surg Am* 2009; 34(5): 945-52.
- [15] Soyer AD. Fractures of the base of the first metacarpal: current treatment options. *J Am Acad Orthop Surg* 1999; 7(6): 403-12.
- [16] Rolando S. Fracture of the base of the first metacarpal and a variation that has not yet been described 1910. *Clin Orthop Relat Res Jun* 1996; 327: 4-8.
- [17] Kahler DM. Fractures and dislocations of the base of the thumb. *South Orthop Assoc* 1995; 4(1): 69-76.
- [18] Massart P, Bèzes H. Screw or mini-plate fixation in fractures of the first metacarpal. Experience with thirty-nine cases. *Ann Chir Main* 1982; 1(4): 29